

## Radial club hand deformity – The continuing challenges and controversies

Banskota AK<sup>1</sup>, Bijukachhe B<sup>2</sup>, Rajbhandary T<sup>3</sup>, Pradhan I<sup>4</sup>, Singh A<sup>5</sup>

<sup>1</sup>Professor and Preceptor, <sup>2,3</sup>Orthopaedic Registrar <sup>4</sup>Assistant Professor, Kathmandu University, <sup>5</sup>Orthopaedic Surgeon, Kathmandu University Medical School

### Abstract

The records of 27 patients with Radial club hand deformity attending the Hospital and Rehabilitation Centre for Disabled Children (HRDC) were reviewed. This longitudinal intercalary deficiency of forearm growth has a varied clinical presentation and the goals of management are both improved function and cosmesis. We present the results of our treatment and review the current world literature on this challenging orthopaedic deformity.

**Key words:** Radial Club Hand, Challenges, Controversies.

The reported incidence of this condition varies from one per 30,000 to 50,000 live births<sup>(1,2,3,4)</sup>. Over a period from 1985 to 2003, we have encountered 27 cases of Radial Club hand deformity. Since the patients present late, most of them demonstrate a reasonable degree of dexterity and independence in activities of daily living (ADLs). Thus, it is difficult to decide on the indications for surgical intervention. The cosmetic concerns of the family members are uniformly significant. Given the context of our present socio-economic condition, decision making to correct a functional deformity in an extremity can become controversial.

### Materials and Methods

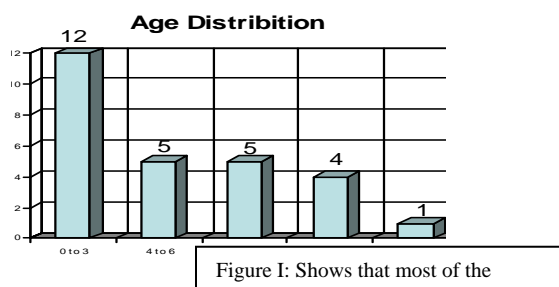
This is a retrospective study carried out at The Hospital and Rehabilitation Centre for Disabled Children (HRDC) covering a time period of 18 years

(1985 to 2003). Medical records of patients admitted with a diagnosis of congenital radial club hand were reviewed for patterns of deformity, associated anomalies, haematological parameters and x-rays were retrieved for detailed analysis. The type of treatment provided and the results of treatment were analyzed for each case.

### Results

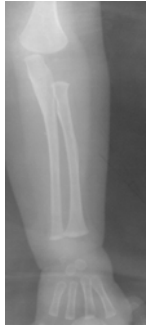#### Chart I

Eight patients had bilateral involvement. In unilateral involvement, there was male preponderance in the ratio of 3:1 where as bilateral involvement was equal. Both sides were equally involved. In this retrospective study Type IV deformity was found to be the most common (19 cases) followed by Type III (9 cases), Type II (2 cases) and Type I (5 cases).



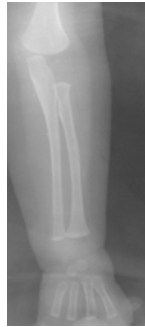### Correspondence

Prof. Ashok K. Banskota  
Professor and Preceptor,  
Kathmandu University Medical School



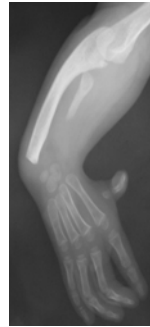*Deficient growth of distal radius*

*I*



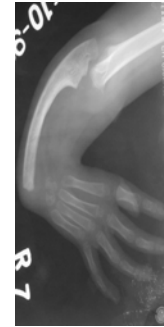
*Both proximal and distal growth deficient (Hypoplastic radius)*

*II*



*Partial absence of the radius*

*III*



*Complete absence of the radius*

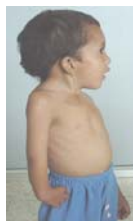*IV*

**Table 1**

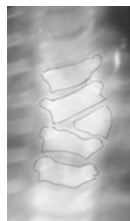<i>Total no. of patients</i>		<i>Side</i>			<i>Total hands</i>	<i>Type of deformity</i>			
27		<i>Right</i>	<i>Left</i>	<i>B/L</i>		<i>I</i>	<i>II</i>	<i>III</i>	<i>IV</i>
<i>Male</i>	<i>Female</i>								
18 (67%)	9 (33%)	10	9	8	35	5	2	9	19

**Table 2** Radial Club hand with other associated anomalies:

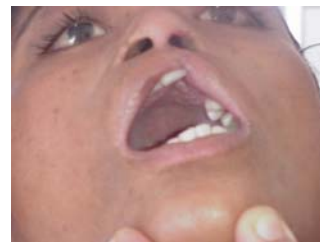<i>Associated anomalies</i>	<i>Deformity type</i>
<i>Klippel Feil syndrome with Sprengel's deformity</i>	<i>IV</i>
<i>Congenital scoliosis with D6 Hemivertebra</i>	<i>IV</i>
<i>Cleft lip/Palate and Radio-Capitellar Synostosis</i>	<i>I</i>
<i>Atrial septal defect (Holt-Oram Syndrome)</i>	<i>IV</i>



3 years old boy with radial club hand associated with Klippel-Feil Syndrome and Sprengel's deformity.



X-ray AP view of thoracic spine showing hemivertebra at D6 level.



14 years old girl had B/L radial club hand associated with cleft lip and palate.

**Table 3.** Thumb anomalies

<i>Thumb deformity</i>	<i>Number</i>
<i>Complete absence</i>	<i>19 hands</i>
<i>Floating thumbs</i>	<i>12 hands</i>
<i>Type III A</i>	<i>3 hands</i>
<i>Type III B</i>	<i>3 hands</i>

We have not encountered as yet a single case of TAR syndrome.

Charts reviewed revealed that all patients had been subjected to a thorough physical examination to rule out other associated anomalies. Complete blood counts, including platelet counts had been done in all the cases. In addition to examination of the involved extremity, x-ray of the spine was also done in all suspected cases for vertebral anomalies. Echocardiography was done in one case with a heart murmur.

Regional examinations of the affected hand were performed to evaluate the degree of deviation and bowing. Thumb Hypoplasia was classified according to Graham TJ et al. Mobility of other fingers were evaluated. Functional status of the hand and elbow was evaluated. Rehabilitation potential of the patient and the expectations of the family were critically considered.

Surgery was performed in only 6 cases.

### **Conservative Treatment**

Twenty-nine hands were managed conservatively and this treatment consisted of;

1. Stretching with serial casts and splints targeting functional positions of the joints.
2. Intensive exercises to improve activities of daily living, targeting improved grasp and pinch.

The children selected for non-operative treatment had the following characteristics;

1. Very small, age-wise, and unlikely to succeed with long term follow-up regimes.
2. Compromised elbow joint motion, whereby function might be critically hampered if the outcome of intervention was even marginally worse.
3. Patients and families with unreal expectations of surgical intervention.

When the parents of the patients were judged to be capable of continuing therapy measures safely at home, they were followed up on a 3 monthly basis at the Hospital or in the outreach clinic.

### **I. Conservative treatment group:**


All the hands (n=29) in this group of patients (n=21) were uncosmetic but with reasonable function and dexterity. Treatment consisting of stretching, splinting or casting was able to achieve mild to moderate degrees of improvement in deformity correction and grasp. This led to more efficient ADLs.



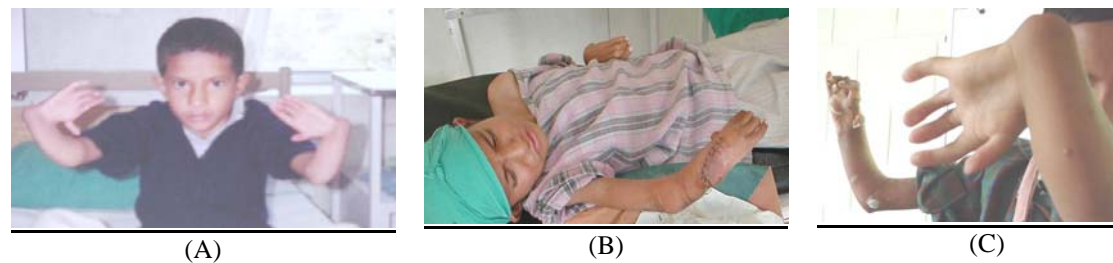
Figure IV: A girl with B/L radial club hand. She has independent ADLs

**II. Surgically treated group:**

Cosmesis improvement was achieved in all six cases treated for deformity correction and centralization. The wrist joint became stable but stiff, and this compromised dexterity and hand function in all six cases.



**Figure V:** (A) Unilateral Radial Club Hand. (B) Primary stretching of the radial soft tissues with the use of Ilizarov’s ring fixator (C) X-ray showing application of the ring fixator. (D) Ulna was centralized and the forearm was immobilized in cast. (E) After removal of the cast 6 weeks post operatively. Pin was removed in 3 month post-operative.



**Figure VI:** (A) 7 years boy with B/L radial club hand deformity (B) 2 weeks after the centralization of ulna (C) 6 week after surgery. Corrected hand is being compared with uncorrected left hand.

**Discussion**

As the case loads in our centre reflects, the most difficult challenge in the management of radial club hand is the untreated patient presenting late for management. In such a situation, the benefits of late surgical intervention have to be critically weighed against the risks, especially the deterioration of existing function.

The treatment plan should ideally begin at birth with serial casting to avoid soft tissue contracture along the volar and radial side of the wrist. Improvement in cosmesis without compromising any function is the

goal of any treatment regime. Contrary to the reports of previous authors the HRDC caseload presents a group of untreated patients with severe deformities.

Early treatment must focus on splinting the club hand to prevent contractures along the volar and radial side of the wrist. Riordan has advocated surgical treatment in the ideal circumstances from as early as 6 weeks to 6 months age <sup>(2)</sup>. Other authors have also recommended early reconstructive intervention <sup>(4, 5, 6)</sup> and it has been recommended not be delay surgery beyond 2 years.

The age at the first evaluation at HRDC of the youngest patient in this series was 3 months and that of the oldest patient was 15 years.

Although much has already been written about the evaluation and management of the radial club hand, the problems faced in this group of patients at HRDC are unique. Because of the remarkable ability of the majority of these patients to function adequately, our treatment was biased towards non-operative treatment measures. Did these measures help the patients significantly? It has been reported that bracing becomes ineffective after the age of 3 years as the carpus slides off the distal aspect of the ulna with forearm growth. The soft tissue contractures and tightness increase further.

The result of intervention for the six cases that underwent surgery are not encouraging. When surgical intervention is at an inappropriate age, the chances of losing adaptive function of the hand increase. Cosmetic gain over functional loss is certainly not a goal to aspire for!

When a child with a radial club hand is first seen, it is of paramount importance to define clearly the goals of treatment and the time frame in which to intervene. From the review of literature on this interesting subject, it is clear that optimum results of both conservative and operative treatment can be anticipated, if the interventions are undertaken at the appropriate time. The issues to be critically reviewed are centralization of ulna, reconstruction of the thumb when indicated and stabilization of the wrist joint. The treatment for radial club hand ideally begins at birth with serial casting to achieve forearm and carpus alignment. Night bracing is then continued till the centralization procedure is undertaken at an appropriate time after 1 year of age, but not later than 2 years of age according to most authorities<sup>(4, 5, 6, 7)</sup>. The technique of centralization is similar fundamentally as originally described by Sayre in 1893<sup>(9)</sup> and expounded biomechanically by Lidge<sup>(8)</sup>.

Attention is then directed to the thumb and the child's functional ability is carefully reviewed prior to any surgical intervention. Salter recommends pollicization of one side only in bilateral involvement<sup>(5)</sup> whereas Kleinmann and Lamb advocate pollicization in unilateral involvement also<sup>(10, 11)</sup>. We at HRDC encountered Type IV deformity to be the commonest followed by Type III, Type II and Type I respectively, and we have no experience with

pollicization in radial club hands. Where good adaptation and function is established in the case presenting late, reconstructive surgery needs to be undertaken very judiciously. The stabilization of the wrist alters the position of the functional ulnar oriented hand and it is possible that ADLs might be adversely affected for patients who undergo surgery at an older age. The advantages of surgical intervention at an appropriate age have been reported by numerous authors.

#### **Acknowledgement**

I am thankful to Dev Ashish Malakar, Research Secretary, HRDC and B & B Hospital.

#### **Conclusion**

This review of the HRDC case load of congenital radial club hand deformity in 27 patients highlights important points to consider in planning the management of this challenging problem. Appropriate surgical intervention at the appropriate age is key for a good outcome and function must never be compromised over cosmetic gain.

#### **References**

1. O'Rahilly, R.- Radial Hemimelia and the functional anatomy of the carpus. *J Anat.*1946; 80: 179
2. Riordan, D.C. - Congenital absence of radius, *J Bone and Joint Surg.* 1955; 37 A: 1129.
3. Lamb, D.W. - Radial Club Hand, *J Bone and Joint Surg.*1977; 53 A: 1.
4. Goldberg MJ and Meyne M - The Radial club Hand, *Orthop. Clin. North Am* 1976; 7 : 341, 1976
5. Flatt AE - The case of congenital hand anomalies, St. Louis, 1977, The C.V. Mosby co.
6. Salter RB - Textbook of disorders and injuries of the musculoskeletal system, Baltimore, 1970, Williams and Wilkins Co.
7. Tachdjian MO - Pediatric orthopedics, Philadelphia 1972, W.B. Saunders Co.
8. Lidge RT - Congenital Radial deficient Club hand, *JBJS* 51 A 1969: 1041.
9. Sayre RH - A contribution to the study of club hand, *Trans Am. Orthop. Assoc.*1893; 6:208.
10. James W. Strickland, James B. Steichen, *Difficult problems in Hand Surgery*, Mosby 1982
11. Lamb, D.W., The treatment of Radial Club Hand: *Hand* 4; 22, 1972.